

## The Natural Progression of Atherosclerosis in an Untreated Patient With Hyperlipidemia: Assessment via Cardiac PET

Richard M. Fleming, M.D., F.I.C.A., F.A.C.A., A.S.N.C.

The Fleming Heart & Health Institute, Omaha, Nebraska

**Abstract.** Recent studies have demonstrated successful reversibility of atherosclerosis in 1/3 of the cases, stabilization in 1/3, and continued progression in the remaining 1/3 of individuals treated for hypercholesterolemia and stress reduction. However, no reported data exist about the natural progression of untreated coronary artery disease in the clinical setting with which these results can be compared. In this case report, we will review the natural progression of atherosclerosis as documented by positron emission tomography (PET) imaging during a 104-day period.

### Introduction

Animal research has demonstrated the development of atheromatous plaques in primates in as little as 1 to 2 weeks following placement on a hypercholesterolemic diet. The Tarahumaran Indians, who have little heart disease while consuming their native diet, have demonstrated significant increases in lipid levels in as little as 4-6 weeks after being placed on a diet high in calories, cholesterol, and saturated fat, but it is not known whether these changes translate into differences in myocardial blood flow. A few studies [1-6] have looked at reducing cholesterol levels in addition to looking for changes in myocardial blood flow but it is unclear whether these results (regression, remodeling, or stabilization) represent improvement or the natural course of atherosclerotic disease.

The question constantly arises whether differences seen in clinical atherosclerosis trials represent successful intervention or the natural progression of disease, since there are no clinical trials or case studies available for comparison. In this case report we will take advantage of a unique opportunity to follow the natural progression of atherosclerotic disease over a 104-day period as assessed by cardiac positron emission tomography (PET) imaging. This is the first

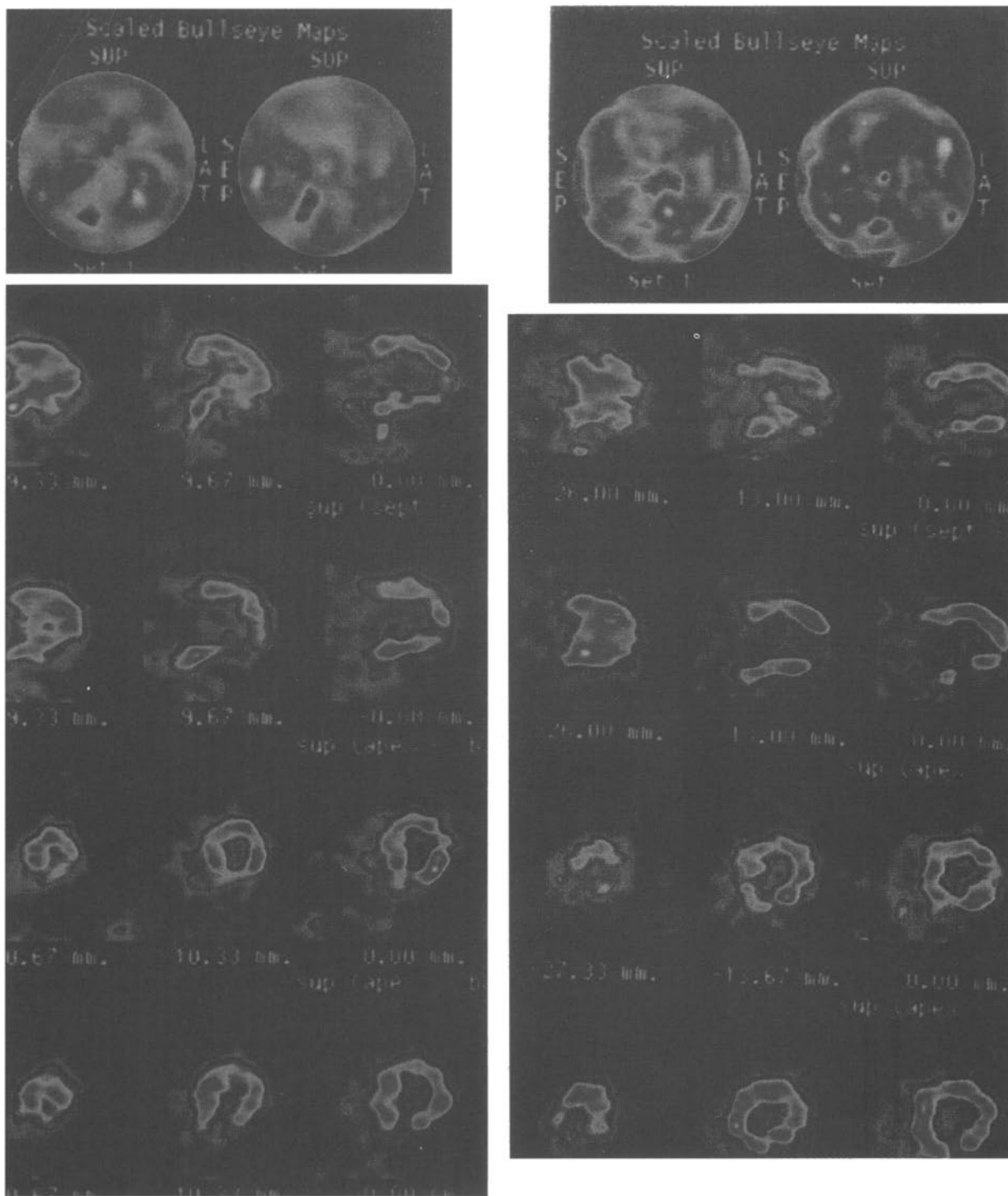
such case report looking at the natural progression of atherosclerosis as assessed by both changes in lipid levels and myocardial perfusion imaging, and provides insight into both the natural progression of atherosclerosis and the potentially aggressive nature of this disease.

### Case Report

Mr. W.C. is a 41-year-old married caucasian with three children (ages 5 years, 3 years and 11 months) who worked as a manager trainer for a restaurant chain. He presented to his primary care physician for evaluation of retrosternal chest discomfort which began with exertion and was associated with nausea, diaphoresis, and dyspnea. Over the pursuing 6 months the discomfort increased in frequency and he was evaluated by several cardiologists and underwent a coronary angiogram (CA), which was interpreted as "normal."

A PET study was performed and revealed "mild" right coronary artery disease, but was dismissed as the cause of his chest discomfort because of the "normal"-appearing CA. Subsequently the patient was treated for "stomach" and "musculoskeletal" problems during the next several weeks. One week prior to being evaluated at the Institute, he was admitted to the hospital for recurrent chest pain. Given his clinical presentation he was evaluated and "ruled-out" for an acute myocardial infarction. An echocardiogram was performed and interpreted as normal except for "mild" left ventricular hypertrophy. Upon later review it revealed inferior hypokinesis.

Several days later he was initially seen at the Institute. His physical examination revealed a pale-appearing gentleman who weighed 259 and 1/4 pounds and stood 6 foot tall. His blood pressure was 128/96 in the right arm sitting with a sinus heart rate of 68 bpm and a respiratory rate of 14. His fundoscopic examination revealed no hollenhorst plaques. The carotid upstrokes were normal and without bruit. The skin was free of xanthomas and xanthalassmas. His cardiovascular examination revealed a fourth apical heart sound but was otherwise normal as was his pulmonary examina-



**Fig. 1.** Initial and follow-up (104-day) PET study. The images on the left half show results obtained at the time of the initial study, while the right half demonstrates the results obtained 104 days later. Images are qualitatively displayed using grey scale with white being the greatest blood flow (isotope) and black being the absence of blood flow (isotope). Each study is divided into three sets of images. The top image shows a "bullseye equivalent" image, first at rest and then with pharmacologic stress. This reveals the apex in the middle of each circle, with the anterior wall at the twelve o'clock position, the lateral wall at three o'clock, the inferior wall at six o'clock, and the septal region at nine o'clock. The next two rows represent the horizontal long axis images (rest in first row, stress in second row) with the anterior wall at 12 o'clock, the apex at

3 o'clock, and the inferoposterior region at 6 o'clock. The last two rows (rest in first row, stress in second row) represent the short-axis views with the same orientation as that used for the "bullseye equivalent" image, except that the center of these images represent the left ventricular chamber where tracer activity should be absent. In the initial study there is decreased tracer activity in the inferior and apical regions consistent with right coronary artery disease (RCA). There is also some early disease noted in the anterolateral (2 o'clock) position. On the second study, the amount of disease is worse as noted by the change in color and the amount of myocardial tissue involved. These areas are consistent with the symptoms of nausea, dyspnea, and angina with left arm pain, and represents a progression of disease over the 104-day period.

tion. There were no abdominal bruits, no peripheral edema and his peripheral pulses were normal.

He was immediately started on a calcium channel blocker, nitrates, beta-blocker, and statin medication. He was also given a prescription for PRN sublingual nitroglycerin. At this time he did not recall having a prior PET scan and he was subsequently scheduled for his second PET study to determine the severity of his existing heart disease.

## Methods

### *Cardiac Positron Emission Tomography*

Cardiac PET is performed with the patient in the fasting state to reduce potential errors resulting from changes in gastrointestinal blood flow. All medications were discontinued 24 hours prior to the study. The patient underwent continuous hemodynamic (BP and HR) and 12-lead ECG monitoring throughout the entire study.

The patient first underwent attenuation correction imaging. After completion of the attenuation study, emission studies were completed, first at rest and later with pharmacologic stress. While more than one protocol [7] exists for PET imaging, this study was conducted using Rb-82 for myocardial perfusion imaging (MPI) and adenosine for pharmacologic stress. The results of the first and second study are shown in Figure one.

## Results

### *Response to the Treatment of Hyperlipidemia and Associated Angina*

Following initiation of cardiac medications the patient experienced a dramatic reduction in the number of anginal episodes. On three occasions he experienced exertional anginal, the first required two sublingual nitroglycerin (SL-NTG) for angina relief, and the later two episodes required only one SL-NTG. Significant weight loss and lipid reduction was easily accomplished once the patient changed his dietary regimen as directed [1–2,8–9]. During this same time he experienced a 3.5-pound weight loss, reduced his total cholesterol by 57%, his LDL-cholesterol by 65% and his triglyceride levels by 65%, as shown in Table 1.

### *Changes on PET Myocardial Perfusion Imaging*

The appearance of MPI defects on the initial PET image demonstrated disease in both the right coronary (RCA) and apical regions, which progressed over the course of the next 104 days despite weight loss and reductions in serum lipids. The second PET study revealed a progression of disease in the inferoapical region along with the appearance of disease in the left circumflex artery.

## Discussion

The case presents several important issues. The *first* is that the successful lowering of serum lipid levels alone does not

**Table 1.** Weight and lipid changes

	Baseline	3 Weeks	Change (%)
Weight	259-1/4 pounds	255-3/4 pounds	-3.5 pounds
Total cholesterol	219 mg/dl	94 mg/dl	-125 mg/dl (-57.1%)
Triglycerides	488 mg/dl	170 mg/dl	-318 mg/dl (-65.2%)
Low density lipoprotein cholesterol	89 mg/dl	32 mg/dl	-57 mg/dl (-64.0%)
High density lipoprotein cholesterol	32 mg/dl	28 mg/dl	-4 mg/dl (-12.5%)
Very-low density lipoprotein cholesterol	98 mg/dl	34 mg/dl	-64 mg/dl (-65.3%)

guarantee reversal of heart disease. Clearly there is more than just cholesterol involved in the pathogenesis of vascular disease [10] and each of these factors must be addressed to successfully improve coronary [7,11] blood flow.

Despite multiple published papers [12–16] reporting errors made in performing and reading CAs, the anatomic information derived from these studies continues to be regarded as a type of gold standard despite misleading results which can lead to misdiagnosing CAD. A better gold standard would appear to be an assessment of myocardial perfusion imaging or a combination of both approaches. Most important, the aggressiveness of CAD based upon stenosis flow reserve (SFR) data [3,4,11] and this patient's PET study serves to remind us that this disease is not only deadly, but quite virulent. If this case study is indicative of atherosclerosis in general, then this disease itself (as predicted) is quite progressive, particularly after SFR drops below 4.0 and treatments [10] which result in its stabilization or reversal/remodeling should be considered successful.

## Conclusion

The natural progression of atherosclerosis, although proposed, has not been clearly demonstrated previously because of an absence of case reports or clinical trials designed to investigate the progression of disease in individuals known to have coronary artery disease. This case report provides proof positive of the aggressive tendency of this disease as well as the speed with which it can advance. This is consistent with changes in SFR [3,4,11] predicted from changes in diameter stenosis. This report not only supports the successful outcomes seen with regression/remodeling/stabilization of disease, but emphasizes the importance of detection of CAD and treatment of each of the factors known to cause atherosclerosis.

## References

1. Fleming RM, Ketchum K, Fleming DM (1995) Treating hyperlipidemia in the elderly. *Angiology* 46:1075–1083.
2. Fleming RM, Ketchum K, Fleming DM (1996) Assessing the inde-

- pendent effect of dietary counseling and hypolipidemic medications on serum lipids. *Angiology* 47:831–840.
3. Fleming RM, Harrington GM (1994) Quantitative coronary arteriography and its assessment of atherosclerosis. Part 1. Examining the independent variables. *Angiology* 45:829–833.
  4. Fleming RM, Harrington GM (1994) Quantitative coronary arteriography and its assessment of atherosclerosis. Part 2. Calculating stenosis flow reserve directly from percent diameter stenosis. *Angiology* 45:835–840.
  5. Ornish D, Brown SE, Scherwitz LW, et al (1990) Can lifestyle changes reverse coronary heart disease? *Lancet* 336:129–133.
  6. Fleming RM. The clinical importance of risk factor modification: looking at both myocardial perfusion imaging (MPI) and myocardial viability (MV). Submitted June 1999, *Int J Angiol*.
  7. Fleming RM (1999) Nuclear cardiology: Its role in the detection and management of coronary artery disease. In: Chang JC (ed). *Textbook of Angiology*. Springer-Verlag: New York; pp 397–406.
  8. Fleming RM (1997) *How to Bypass Your Bypass: What Your Doctor Doesn't Tell You About Cholesterol and Your Diet*. Rutledge Books: Bethel, CT.
  9. Fleming RM (1998) *The Diet Myth and Keeping Your Heart Forever Young*. Windsor House Publishing Co.
  10. Fleming RM. Chapter 64. The pathogenesis of vascular disease. In: Chang JC (ed). *Textbook of Angiology*. Springer-Verlag: New York; pp 787–798.
  11. Fleming RM (1999) Atherosclerosis: Understanding the relationship between coronary artery disease (CAD) and stenosis flow reserve (SFR). In: Chang JC (ed). *Textbook of Angiology*. Springer-Verlag: New York; pp 381–387.
  12. Detre KM, Wright E, Murphy ML, Takaro T (1975) Agreement in evaluating coronary angiograms. *Circulation* 52:979–986.
  13. Zir LM, Miller SW, Dinsmore RE, Gilbert JP, Harthorne JW (1976) Interobserver variability in coronary angiography. *Circulation* 53:627–632.
  14. DeRouen TA, Murphy JA, Owen W (1977) Variability in the analysis of coronary arteriograms. *Circulation* 55:324–328.
  15. Fleming RM, Kirkeeide RI, Smalling RW, Gould KL (1991) Patterns in visual interpretation of coronary arteriograms as detected by quantitative coronary arteriography. *J Am Coll Cardiol* 8:945–951.
  16. Fleming RM, Fleming DM, Gaede R (1996) Teaching physicians and health care providers to accurately read coronary arteriograms. *Angiology* 47:349–359.