
R. Fleming, M.D.

THE EVOLUTION OF NUCLEAR CARDIOLOGY TAKES US BACK TO THE BEGINNING TO DEVELOP TODAY'S "NEW STANDARD OF CARE" FOR CARDIAC IMAGING: HOW QUANTIFYING REGIONAL RADIOACTIVE COUNTS AT FIVE AND 60 MINUTES POST-STRESS UNMASKS HIDDEN ISCHEMIA

Richard M. Fleming, M.D., FACP, FASNC; Gordon M. Harrington, Ph.D.; Riaz Baqir, M.D.; Scott Jay, M.D.; Sridevi Challapalli, M.D.; Kayla Avery, M.D.; Jim Green, M.D.
Reno Nevada Cardiology, Reno, Nevada

Introduction

In 1926, Blumgart[1] published the first paper on nuclear cardiology. He demonstrated that a radioactive isotope injected into the venous system of the right arm could be sequentially measured over the next several minutes by calculating the amount of radioactivity in the arterial system of the left arm. This was termed "circulation time," and the longer the time required for detection, the weaker the heart muscle. It also established the need for multiple images under the same state of stress. By 1959, Gorlin[2] demonstrated that resting studies could not be used to evaluate ischemia,[3,4] which later proved to be the result of coronary flow reserve, a phenomenon associated with vasodilatory capacity of coronary arteries under stress and not under resting conditions.

The prognosis for nuclear cardiology was critical by the mid 1960s, when Love[5] pointed out that there were no useful isotopes available to clinically evaluate the patient. This was remedied with the introduction of thallium-201 in 1975. By the late 1980s, the search for better imaging agents lead to the production of several compounds using the isotope technetium-99m. Despite the promise of rapid uptake and release, some of these agents[6] would prove to be difficult to use in everyday practice. By contrast, the more lipophilic compound, sestamibi, would prove to be easier to use. Unfortunately, most clinical studies were being performed with rest-stress imaging for comparison despite the teachings of Blumgart and Gorlin.

By 1993, Crane[7] established that sestamibi did not merely enter cells and remain there but underwent uptake and release dependent upon the level of ischemia present, which influenced mitochondrial calcium. In recent years, this understanding has been applied extensively in other areas of nuclear medicine to better detect disease and in some instances to better understand the responses of certain cancers to treatment.[8-10] This knowledge of cellular and subcellular organelle (mitochondrial) uptake and release (washout) has yielded a better understanding and detection of congestive heart failure.[11-14] cardiomyopathies,[15-17] Prinzmetal's angina,[18,19] and ischemia.[11, 13, 20-23]

Recently, our group completed work demonstrating improved detection of ischemia and vulnerable plaque,[24-26] which had been impossible to detect when comparing resting images to stress images. This report shares both a description of this new standard of care in cardiac imaging and an example of its contribution to clinical cardiology.

Case Example

Mr. P is a 58-year-old Caucasian male who was admitted to the hospital for further evaluation of exertional chest discomfort. His evaluation had included a history and physical, electrocardiogram (ECG), exercise stress test, echocardiogram, and an echocardiographic stress test. His diagnostic studies found no evidence of ST changes by ECG or by treadmill stress. The echocardiogram revealed no regional wall motion abnormalities, and stressing the patient by treadmill did not revealed exertional wall motion problems. His internist wanted to avoid a cardiac catheterization given these "normal" findings. Concerned with the patient's description of exertional discomfort, a myocardial perfusion imaging study (MPI) was ordered. The results of comparing rest to stress images are shown in Figure 1. In an effort to exclude tissue attenuation artifacts, the institution also employed attenuation correction, which is also shown in Figure 1. The conclusion of this study was that the patient did not have ischemia. The patient returned to his telemetry bed to prepare for hospital discharge, at which time he demonstrated ST elevations on the monitor.

In addition to the use of resting and stress images, we had obtained a second set of post-stress images at five minutes post stress using the protocol shown in Figure 2. The findings from this study were completely different and pointed to disease in his left anterior descending artery system. The five-minute post stress imaging results are shown in Figure 3. The results of the findings at five minutes post stress were then compared with results obtained at 60 minutes post stress. The difference (redistribution/washout) is the difference or the change that has occurred over time.

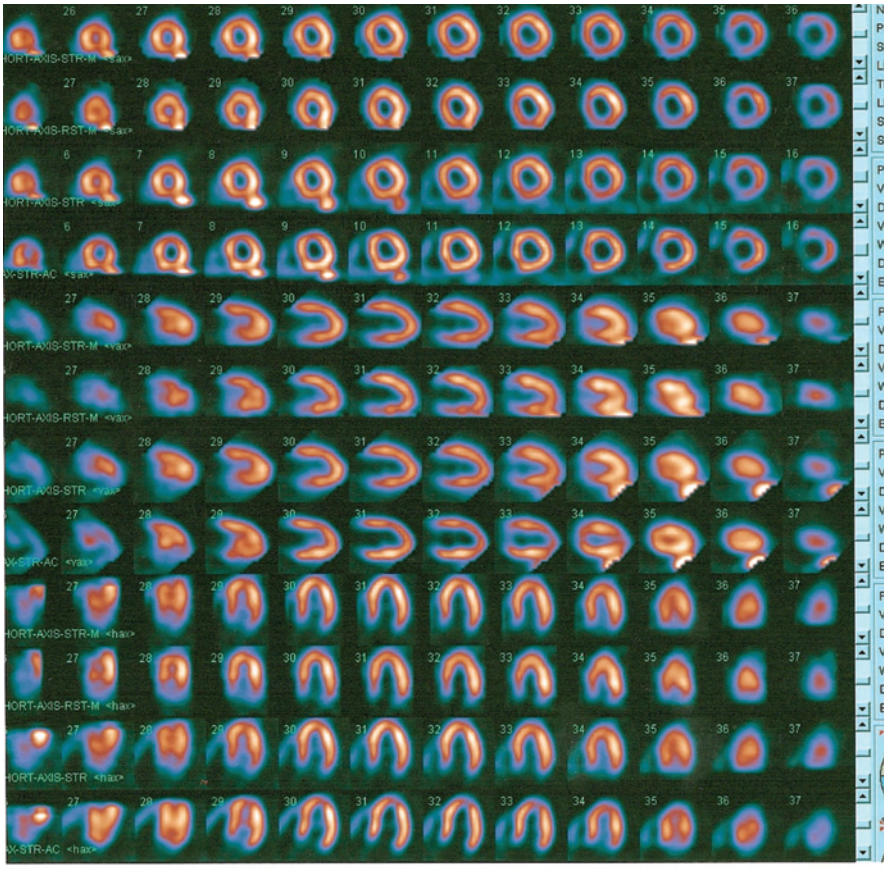

Figure 1. Dynamic resting image to assess myocardial damage (MII) and dynamic stress image to assess ischemia with and without attenuation correction (AC).

The same patient shown in figures 2, 3, 5 and 6 is displayed using coronal short axis (top 4 rows), vertical long axis (rows 5-8) and the horizontal long axis (rows 9-12). Rows 1-2, 5-6, and 9-10 show images using nonattenuation-corrected images. Rows 3-4, 7-8, and 11-12 show the same regions using AC. Rows 2, 4, 6, 8, 10 and 12 show resting images providing information regarding myocardial (MII) infarction/injury (infarction, stunned or hibernating) while rows 1, 3, 5, 7, 9 and 11 reveal the same regions of myocardium following pharmacologic stress, in this case adenosine. These images were interpreted as "normal," showing no evidence of infarction or ischemia.

As shown in Figure 2, the amount of technetium that should be present in an area if there was the same amount of isotope in that region at both five and 60 minutes would be 10% less. This means that, if there is no disease, the isotope count for the entire heart at five minutes (374,930) (Figure 3) should reduce by 10% of this amount 55 minutes later. This would have yielded a count of 337,437 (90% of 374,930) at 60 minutes. Instead, the total heart count was actually 216,886. Clearly, the isotope does not simply get delivered to the heart and "stick" there like glue. Rather, there is a constant delivery, uptake, and release that depends on ischemia and cellular health, which is itself dependent upon the level of ischemia present.

Given the 10% decay of technetium 99-m, the actual loss of isotope from five minutes to 60 minutes was 42%. This shows that the patient had considerable disease, which was missed using only a single stress image result obtained at 60 minutes post stress. A quick observation shows that the inferior region

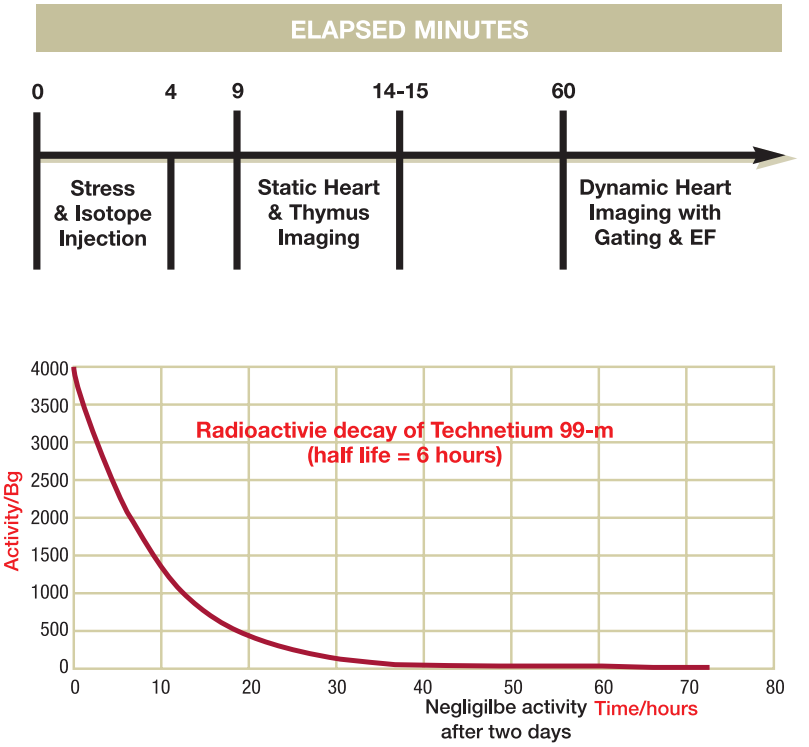

Figure 2. Multiple imaging protocol following stress to calculate quantitative change in sestamibi.

Patients are brought for imaging and undergo stress and isotope injection. While this varies depending upon the type of stress[27] used, the injection of technetium-99m isotope is performed per institutional standards. Five minutes after the injection of technetium isotope, a static (planar) image of the heart is performed[28] to look for evidence of inflammation and to obtain information about tracer activity at five minutes. A second image (tomographic) is obtained 55 minutes later where dynamic images are obtained which can be processed to obtain comparison information regarding tracer activity. Identical regions of interest (ROIs) from the five and 60 minute images are compared. The additional dynamic information can be used to determine wall motion abnormalities and ejection (EF) fraction which is billed for separately. The second part of the figure shows the radioactive decay curves for technetium-99m-isotopes. Between the first and second set of images, there is a 55 minute period of time, which is associated with a 10% decay in isotope. Any additional change is a reflection of ischemia.

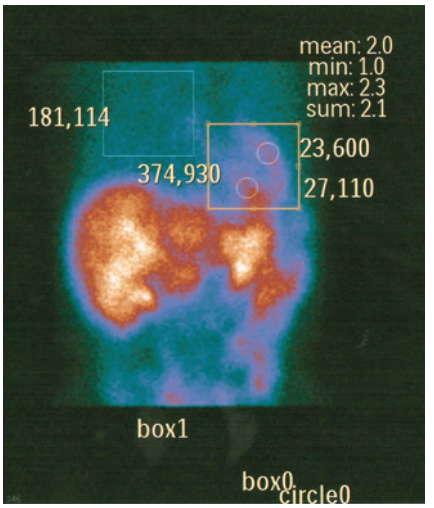

Figure 3. Static image taken at five-minutes post stress with regions of interest defined and quantified.

Static imaging at five minutes with regions of interest (ROI) showing total heart count of 374,930 and total lung count of 181,114, with a calculated heart-to-lung (H:L) ratio of 2.0. The anterior ROI shows a 23,600 count and the inferior ROI shows 27,110.

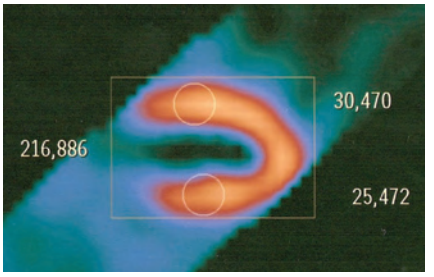

Figure 4. Regions of interest for assessment of washin/washout (WR) at 60 minutes.

Reconstruction of the same myocardial region noted in Figure 3, this time taken from the dynamic image result obtained at 60-minutes post stress. This shows a total heart count of 216,886 in this single plane with total heart counts greater than 1 million, revealing total heart washin. The anterior ROI shows an increase in count activity (washin) of 30,470 compared with the activity of 23,600 (Figure 3) obtained at 5 minutes. The inferior ROI shows a count of 25,472 compared with the count activity of 27,110 (Figure 2) obtained five minutes post stress.

(right coronary artery/RCA) had a five-minute value of 27,110 and a 60-minute value of 25,472 (6% wash-out). The RCA was not the site of disease.

When the anterior region supplied by the left anterior descending artery (LAD) was studied, the five-minute count was 23,600. Instead of decreasing by 10% to 21,240, the count actually increased to 30,470. This increased amount of radioactive counts over time revealed a delay in delivery and uptake of the isotope to a region supplied by a critically narrowed artery and in this case one with a vulnerable plaque. Such arteries are not able to vasodilate on demand[3, 4] and show a delay in isotope delivery. Since the inferior region did not have arterial narrowing and the LAD did, the 60-minute images appear to have equal amounts of tracer activity, leading to the "false normal"-appearing images shown in Figure 1.

The information acquired from the five- and 60-minute images revealed ischemia in the LAD

system that was shown on coronary angiography (Figures 5 and 6). Following stent placement, the patient showed normalization of his ST elevation in the cardiac catheterization laboratory.

Discussion

The sensitivity and specificity of single-photon emission computed tomography has been limited to 65-90% over the last four decades despite improvements in isotopes, nuclear cameras and computers, attenuation correction algorithms, and attenuation rings/bars. One of the first lessons as a medical student is to determine which test to run to diagnose a patient's problem. We are all taught that the results are then compared to what is presumed to be normal. "Normal" is determined by whether or not you have prior studies to compare with. If not, one takes the information obtained from a patient's test and compares it with what is expected. A classic example is poor R-wave progression (PRWP) on an ECG. While this doesn't define damage to the heart's septum, the question is raised in one's mind: Does the PRWP reflect lead placement, body habitus, or actual myocardial damage with loss of myocardium and subsequently electrical activity? The answer is easy to solve if one has a prior ECG of the patient to use as comparison. If R-waves were present the week before but are absent or reduced now, the level of suspicion for myocardial damage increases.

Much of this limitation in nuclear imaging comes from the comparison of rest to stress images. Despite the teachings of Blumgart and Gorlin, physicians have mistakenly concluded that comparing resting images ("apples") to stress images ("oranges") are the way to look for ischemia. However, the knowledge acquired by multiple investigators has demonstrated that this simply isn't true.[7-26] The real genius behind nuclear imaging is that it provides a physiologic measure of what is going on in the body. This can be used to differentiate benign versus cancerous cells, to determine how cancer will respond to treatment, or, as we have seen here, to find hidden disease that appears nonexistent if one waits too long to look for it. Coronary arteries with critically diseased arterial regions — due to almost complete occlusion of the coronary lumen or to vulnerable plaques, both of which impair stenosis flow reserve — will produce a delay in final delivery and equilibration of isotope and subsequently a "false negative" finding on the MPI. Similarly, using our five- and 60-minute multi-imaging protocol, regional problems with attenuation artifacts are eliminated since a region of the heart is being compared with itself over time, much like the PRWP from one ECG to another. Unless there is a change in breast tissue or abdominal girth, septal wall hypertrophy,

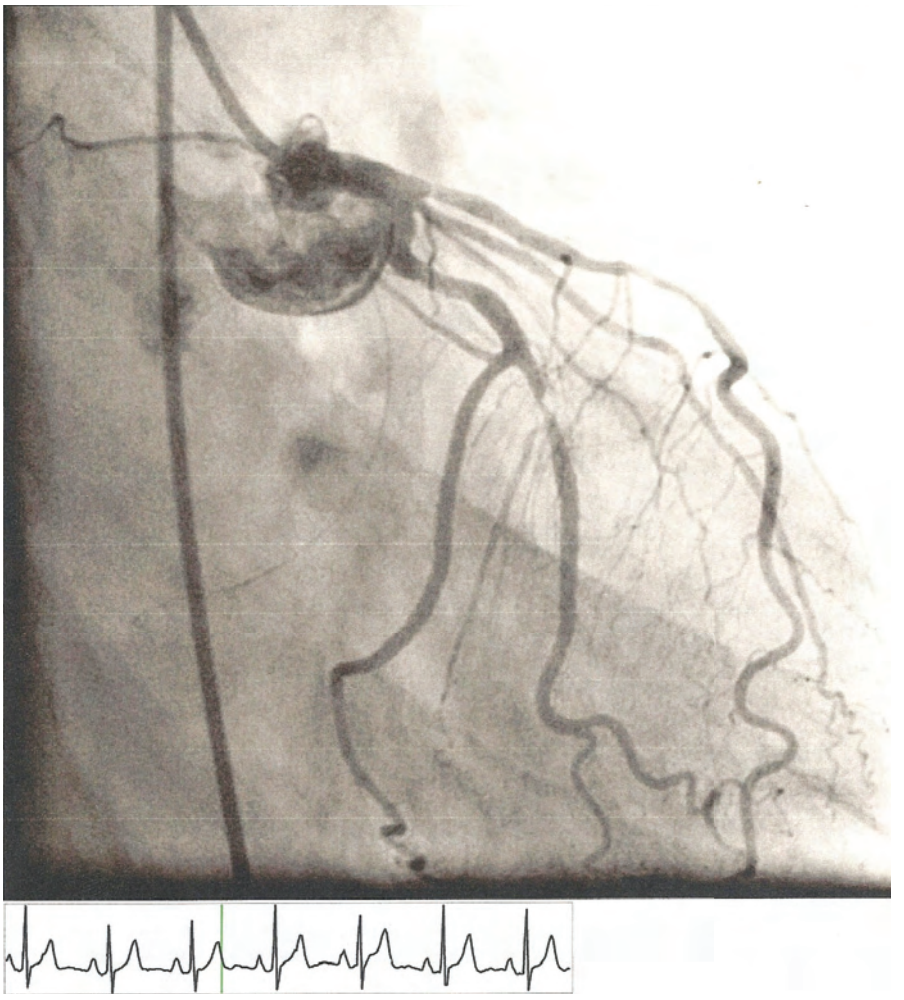

Figure 5. Critically diseased left anterior descending, first diagonal and first obtuse marginal arteries matching washout (WR) data prior to stenting.

Cardiac catheterization revealed a "normal" left main (LM) and right coronary artery (RCA). The left anterior descending (LAD) had an 80% diameter stenosis (DS) ostial (beginning) lesion in addition to a 75% "long segmental" proximal lesion. The first diagonal had a 60% DS lesion at the ostium. The proximal left circumflex (LCx) had a 40% DS proximal and an 80% DS ostial lesion of the first obtuse marginal (OM1).

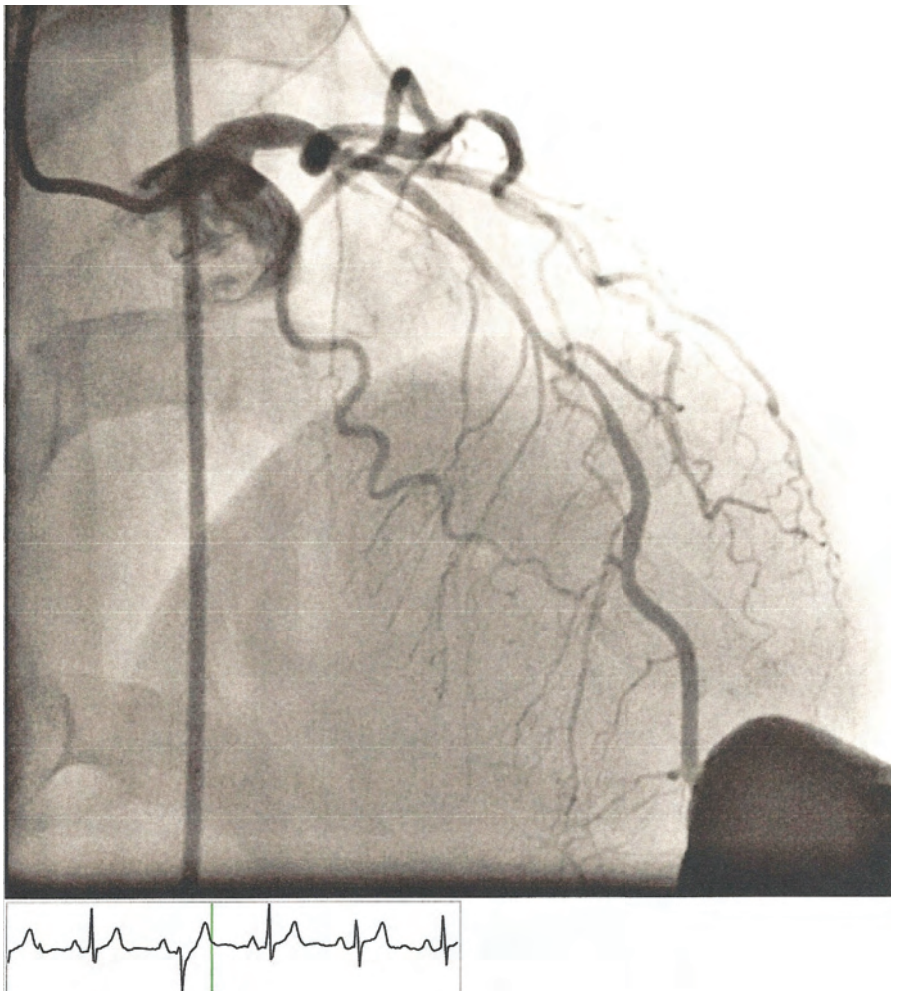

Figure 6. Critically diseased left anterior descending, first diagonal and first obtuse marginal arteries after stenting.

Cardiac catheterization of same arteries shown in Figure 5 following insertion of a Cypher RX drug-eluting 3.5 x 8 mm stent for the 80% DS ostial lesion of the LAD, a Cypher RX drug-eluting 3.0 x 33 mm stent for the 75% DS proximal LAD lesion, and a Cypher RX drug-eluting 3.0 x 13 mm stent for the 80% DS ostial lesion of OM1.

or formation of a bundle branch during the study, the comparison of the amount of radioactive counts in a region of the heart to itself will not be altered over the 55 minutes between the first image and second image, minus the expected 10% decay of sestamibi.

Studies currently underway (Figure 7) are demonstrating that the use of FH (Fleming-Harrington) redistribution/washout/washin can also be used to determine treatment intervention for individuals presenting with acute coronary syndrome.

Conclusion

Upon entering medical school and throughout my education as a cardiologist in Houston, I was trained by great teachers who repeatedly taught us to question how we could best diagnose and treat heart disease. "Based upon the numbers of people whose heart disease is missed using rest-stress imaging (18%), this new FH Redistribution/Washout protocol will detect 40-60,000 individuals who would otherwise be told they have no heart disease, yet have "vulnerable plaques" or "critical lessions" and would subsequently experience an adverse cardiac event (MI, death). Similarly, using the numbers of people who have no disease but are reported to have ischemia by rest-stress imaging[29] and who subsequently experience an unnecessary complication, this new protocol could reduce this number by 4,400 to 8,800 people annually in the United States. As a result, we have now changed the *Standard of Care for Cardiac Imaging.* We now know that multiple sequential imaging of the heart at five and again at 60-minutes post stress using sestambi provides information, which cannot be obtained by comparing rest and stress images. The unmasking of this disease has provided us with the method necessary to find "vulnerable" plaques, unmask critically narrowed arteries that would not be detected using a single 60 minute stress image and more importantly provides the excellence in cardiac care emphasized by our teachers, Drs. DeBakey and Cooley. As they taught us, "average isn't good enough", "excellence is to be strived for." This new standard of care provides this excellence they and their predecessors (Blumgart and Gorlin) called for.

References

1. Blumgart HL, Yens OC. Studies on the velocity of blood flow: I. The Method Utilized. J Clin Invest. 1927 Apr;4(1):1-13.
2. Gorlin R, Brachfeld N, MacLeod C, Bopp P. Effect of nitroglycerin on the coronary circulation in patients with coronary artery disease or increased left ventricular work. Circulation. 1959 May;19(5):705-18.
3. Fleming RM, Harrington GM. Quantitative coronary arteriography and its assessment of atherosclerosis. Part 1. Examining the

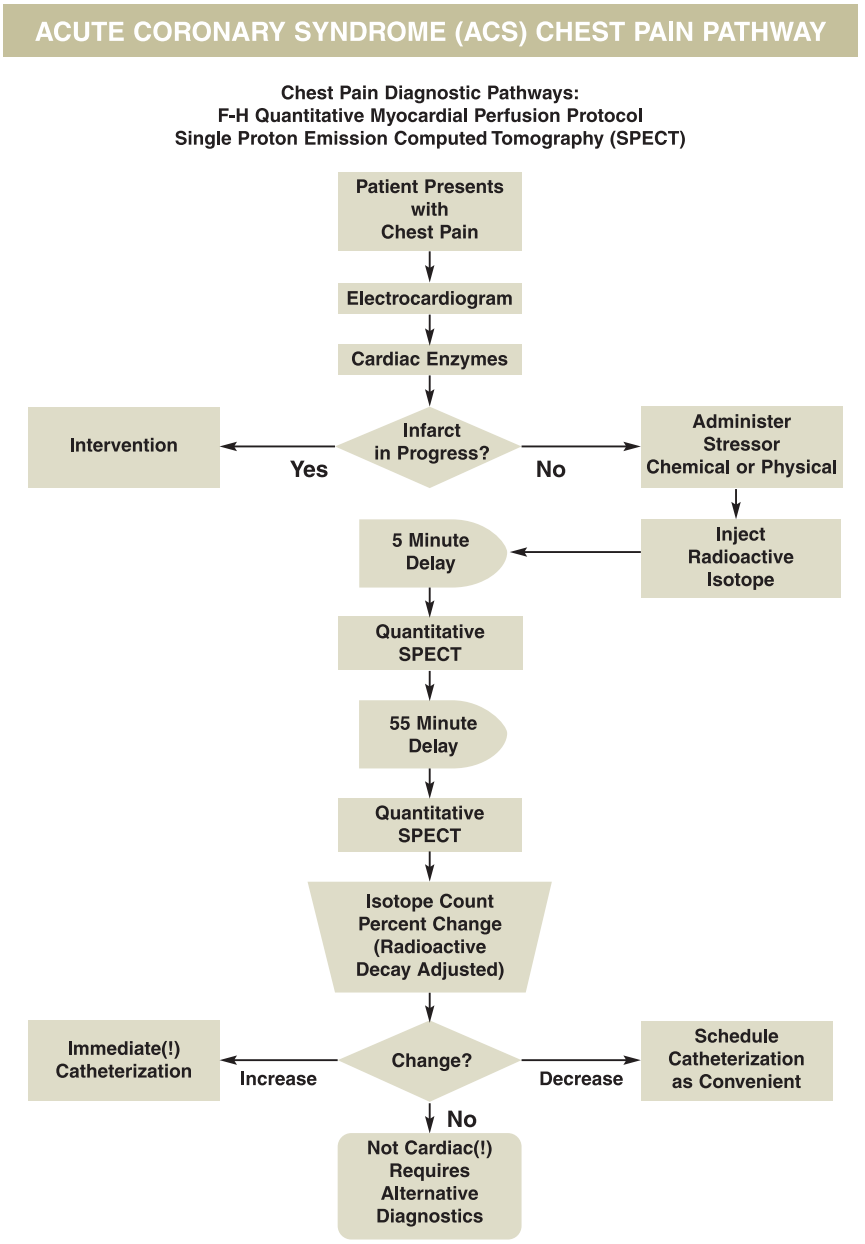

Figure 7. Acute coronary syndrome (ACS) chest pain pathway.

Ongoing research has demonstrated that the use of FH (Fleming-Harrington) washout can also be used in the acute coronary syndrome setting to differentiate treatment intervention.

independent variables. Angiology. 1994 Oct;45(10):829-33.

4. Fleming RM, Harrington GM. Quantitative coronary arteriography and its assessment of atherosclerosis. Part 2. Calculating stenosis flow reserve directly from percent diameter stenosis. Angiology.1994 Oct;45(10):835-40.
5. Love WD. Isotope Technics in Clinical Cardiology. Circulation. 1965 Aug;32:309-15.
6. Fleming RM, Kirkeeide RL, Taegtmeyer H, Adyanthaya A, Cassidy DB, Goldstein R. A comparison of technetium-99m teboroxime tomography with automated quantitative coronary arteriography and thallium-201 tomographic imaging. J Am Coll Cardiol. 1991 May;17(6):1297-302.
7. Crane P, Laliberte R, Heminway S, Thoolen M, Orlandi C. Effect of mitochondrial viability and metabolism on technetium-99m-sestamibi myocardial retention. Eur J Nucl Med. 1993 Jan;20(1):20-5.
8. Sciuto R, Pasqualoni R, Bergomi S, Petrilli G, Vici P, Belli F, Botti C, Mottolese M, Maini CL. Prognostic value of (99m)Tc-sestamibi washout in predicting response of locally advanced breast cancer to neoadjuvant chemotherapy. J Nucl Med. 2002 Jun;43(6):745-51.
9. Gupta Y, Ahmed R, Happerfield L, Pinder SE, Balan KK, Wishart GC. P-glycoprotein expression is associated with sestamibi washout in primary hyperparathyroidism. Br J Surg. 2007 Dec;94(12):1491-5.
10. Chatziioannou SN, Alfaro-Franco C, Moore WH, Alanis-Williams L, Dhekne RD, Ford PV. The significance of incidental noncardiac findings in Tc-99m sestamibi myocardial perfusion imaging: Illustrated by a case. Tex Heart Inst J. 1999;26(3):229-31.
11. Hurwitz GA, Ghali SK, Husni M, Slomka PJ, Mattar AG, Reid RH, Lefcoe NM. Pulmonary uptake of technetium-99m-sestamibi induced by dipyridamole-based stress or exercise. J Nucl Med. 1998 Feb;39(2):339-45.
12. Sugiura T, Takase H, Toriyama T, Goto T, Ueda R, Dohi Y. Usefulness of Tc-99m methoxyisobutylisonitrile scintigraphy for evaluating congestive heart failure. J Nucl Cardiol. 2006 Jan-Feb;13(1):64-8.
13. Kumita S, Seino Y, Cho K, Nakajo H, Toba M, Fukushima Y, Okamoto N, Takano T, Kumazaki T. Assessment of myocardial washout of Tc-99m-sestamibi in patients with chronic heart failure: comparison with normal control. Ann Nucl Med. 2002 Jun;16(4):237-42.
14. Matsuo S, Nakae I, Tsutamoto T, Okamoto N, Horie M. A novel clinical indicator using Tc-99m sestamibi for evaluating cardiac mitochondrial function in patients with cardio-

myopathies. J Nucl Cardiol. 2007 Apr;14(2):215-20.

15. Ikawa M, Kawai Y, Arakawa K, Tsuchida T, Miyamori I, Kuriyama M, Tanaka M, Yoneda M. Evaluation of respiratory chain failure in mitochondrial cardiomyopathy by assessments of 99mTc-MIBI washout and 123I-BMIPP/99mTc-MIBI mismatch. Mitochondrion. 2007 Feb-Apr;7(1-2):164-70.
16. Meissner K, Sperker B, Karsten C, Zu Schwabedissen HM, Seeland U, Böhm M, Bien S, Dazert P, Kunert-Keil C, Vogelgesang S, Warzok R, Siegmund W, Cascorbi I, Wendt M, Kroemer HK. Expression and localization of P-glycoprotein in human heart: effects of cardiomyopathy. J Histochem Cytochem. 2002 Oct;50(10):1351-6.
17. Kazumasa U, Isobe S, Izawa H, Kobayashi M, Hirashiki A, Yamada T, Ohshima S, Kato K, Murohara T, Yokota M. Increased 99m-Tc-sestamibi washout reflects impaired myocardial contractile reserve and prolonged relaxation in patients with nonobstructive hypertrophic cardiomyopathy. J Nucl Med. 2008;49(Suppl 1):189P.
18. Ono S, Yamaguchi H, Takayama S, Kurabe A, Heito T. [Rest delayed images on 99mTc-MIBI myocardial SPECT as a noninvasive screen for the diagnosis of vasospastic angina pectoris] Kaki Igaku. 2002 May;39(2):117-24.
19. Ono S, Takeishi Y, Yamaguchi H, Abe S, Tachibana H, Sato T, Kubota I. Enhanced regional washout of technetium-99m-sestamibi in patients with coronary spastic angina. Ann Nucl Med. 2003 Jul;17(5):393-8.
20. Fukushima K, Momose M, Kondo C, Kusakabe K, Kasanuki H. Myocardial kinetics of (201)Thallium, (99m)Tc-tetrofosmin, and (99m) Tc-sestamibi in an acute ischemia-reperfusion model using isolated rat heart. Ann Nucl Med. 2007 Jul;21(5):267-73.
21. VanBrocklin HF, Hanrahan SM, Enas JD, Nandanan E, O'Neil JP. Mitochondrial avid radioprobes. Preparation and evaluation of 7′(Z)-[125I]iodorotenone and 7′(Z)-[125I]iodorotenol. Nucl Med Biol. 2007 Jan;34(1):109-16.
22. Richter WS, Cordes M, Calder D, Eichstaedt H, Felix R. Washout and redistribution between immediate and two-hour myocardial images using technetium-99m sestamibi. Eur J Nucl Med. 1995 Jan;22(1):49-55.
23. Meerdink DJ, Aleppo JA. Myocardial transport of hexakis(2-methoxy-isobutylisonitrile) and thallium before and after coronary reperfusion. Circ Res. 1990 Jun;66(6):1738-46.
24. Fleming RM, Harrington GM, Baqir R. Use of parabolic model in Tomographic diagnosis of infarction and stenosis. Presented at: The 1st Congress on Controversies in Cardiovascular diseases: Diagnosis, treatment and intervention (C-Care); July 4, 2008; Berlin, Germany.
25. Fleming RM, Harrington GM, Baqir R, Jay S, Avery K, Wallenmeyer M. The clinical importance of multiple SPECT images following stress — A new standard of care. Presented at: 30th Annual Meeting and Educational Symposium Missouri Valley Chapter of Society of Nuclear Medicine; October 4, 2008; Omaha, NE.
26. Fleming RM, Harrington GM, Baqir R, Jay S, Avery K, Wallenmeyer M. Multiple post stress SPECT imaging unmasks hidden coronary artery disease and eliminates the need for unnecessary cardiac catheterization. It's all about detecting CHANGE! Validating Blumgart's work. Lancet. Forthcoming 2008.
27. Fleming RM. Textbook of Angiology. New York: Springer-Verlag; 1999. Chapter 31, Nuclear Cardiology: Its role in the detection and management of coronary artery disease; p. 397-406.
28. Fleming RM. The Fleming Unified Theory of Vascular Disease: a link between atherosclerosis, inflammation, and bacterially aggravated atherosclerosis (BAA). Angiology. 2000 Jan;51(1):87-9.
29. Fierens E. Outpatient coronary arteriography. Catheterization and Cardiovascular Diagnosis. 2005;10:27-32.